

ption

Connective tissues primarily give structural support to other tissues and organs in the body. Though there are a wide variety of types, all are composed of cells, fibers, and ground substance. The most common cell type, called a fibroblast, manufactures fibers and other extracellular material. The two most common types of protein fibers produced are collagen and elastin. Collagen is for strength and elastin is for elasticity. The cells and the fibers are both embedded in a gel-like material called the ground substance. The ground substance varies in its consistency from being more rigid material.

Loose connective tissues have fewer fibers than other connective tissues and serve as a protective padding in the body. There are three tissues classified as loose connective tissues: *areolar connective tissue*, *adipose connective tissue*, and *reticular connective tissue*.

Adipose connective tissue is fat tissue. It is composed almost entirely of fat cells called adipocytes along with some blood vessels. These cells have a large vacuole to store lipids (*fat*). Though adipocytes are not able to divide, they do change in size by expanding or shrinking depending on the amount of lipid that is stored inside their vacuoles. For example, as a person loses weight, the amount of lipid in the adipocyte's vacuole decreases, causing the cell to shrink in size. Unfortunately, if a person regains that weight, the cells are able to expand back to their original size.

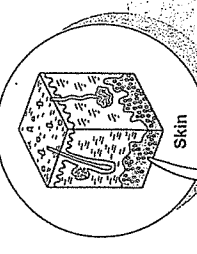
ion

Under all skin but especially in abdomen, buttocks, and breasts; around some organs such as eyeballs and kidneys.

ion


Protects certain organs and other structures; insulates against heat loss through the skin; stores energy as a reserve fuel.

**Location**



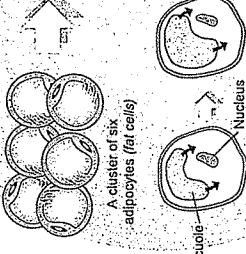
3-D

**Fun Fact:** Excess adipose tissue can be removed by a surgical procedure called liposuction, but it does have some risks.



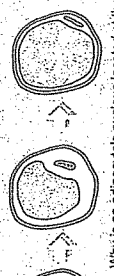
One adipocyte (fat cell)

**Location**



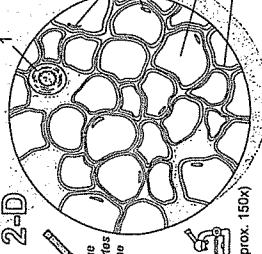
2-D

**Fun Fact:** Why is an adipocyte's nucleus located at the outer edge of the cell? Because the vacuole for lipid storage expands as it fills, and displaces the nucleus and other organelles to the other edge of the cell.




One adipocyte (fat cell)

**Location**



2-D

**Fun Fact:** This tissue type is not specialized, so it does not look like anything in particular. It has a random arrangement of fibers and cells—nothing special!



2-D

**Color the cells and fibers in the same color.**

**Color the cells and fibers in different colors.**

(approx. 150x)

**Key to Illustration**

1. Blood vessel	3. Vacuole for lipid storage	4. Plasma membrane of adipocyte (fat cell)
2. Nuclei of adipocytes (fat cells)		

1. \_\_\_\_\_  
2. \_\_\_\_\_  
3. \_\_\_\_\_  
4. \_\_\_\_\_

My drawing of adipose connective tissue

ption

Connective tissues primarily give structural support to other tissues and organs in the body. Though there are a wide variety of types, all are composed of cells, fibers, and ground substance. The most common cell type is called a fibroblast, which manufactures fibers and other extracellular material. The two most common types of protein fibers produced are collagen and elastin. Collagen is for strength and elastin is for elasticity. The cells and the fibers are both embedded in a gel-like material called the ground substance. The ground substance varies in consistency from being gelatin-like to a much more rigid material.

Loose connective tissues have fewer fibers than other connective tissues and serve as a protective padding in the body. The three tissues classified as loose connective tissues are: *areolar connective tissue*, *adipose connective tissue*, and *reticular connective tissue*.

Areolar connective tissue has a random arrangement of cells, fibers, and ground substance. It contains all the basic components of any connective tissue without being specialized.

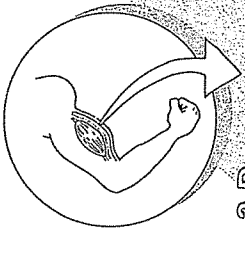
ion

Beneath epithelial tissues all over the body, between skin and skeletal muscles; surrounding blood vessels; within skin; around organs; around joints

ion


Cushions and protects organs; its phagocytes protect against pathogens; holds tissue fluid

**Location**

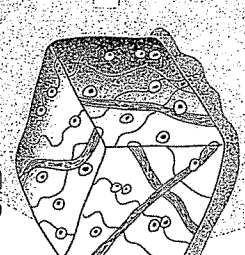


3-D

**Fun Fact:** When hunters skin an animal, the tissue they break to separate skin from muscle is areolar connective tissue.




**Location**



2-D

**Fun Fact:** This tissue type is not specialized, so it does not look like anything in particular. It has a random arrangement of fibers and cells—nothing special!



2-D

**Color the cells and fibers in the same color.**

**Color the cells and fibers in different colors.**

(approx. 200x)

**Key to Illustration**

1. Collagen fibers	2. Elastin fibers	3. Fibroblast nuclei
--------------------	-------------------	----------------------

1. \_\_\_\_\_  
2. \_\_\_\_\_  
3. \_\_\_\_\_

My drawing of areolar connective tissue

**ES—Epithelial**  
Squamous Epithelium

**Location**

Epithelial tissues line internal cavities and passageways and cover external body surfaces. They are composed mostly of cells that rest on a thin basement membrane. No blood vessels are present. One method of classifying epithelial tissues is by the number of layers of cells. Simple epithelia have a single layer of cells, and stratified epithelia have multiple layers of cells. Classification is also based on the following cell shapes: *squamous* (thin, flat), *cuboidal* (cube-shaped), and *columnar* (column-shaped).

Stratified squamous epithelium is of two different types—keratinized and non-keratinized. The bottom layer in either type is composed of cuboidal or columnar cells that are active in cell division. New cells are pushed upward toward the surface. In a process called keratinization the new cells in the keratinized type fill with a protein called keratin. The result is that the outer surface of this tissue is tough and water-resistant.

**Location**

**Keratinized**

- epidermis of skin

**Non-keratinized**

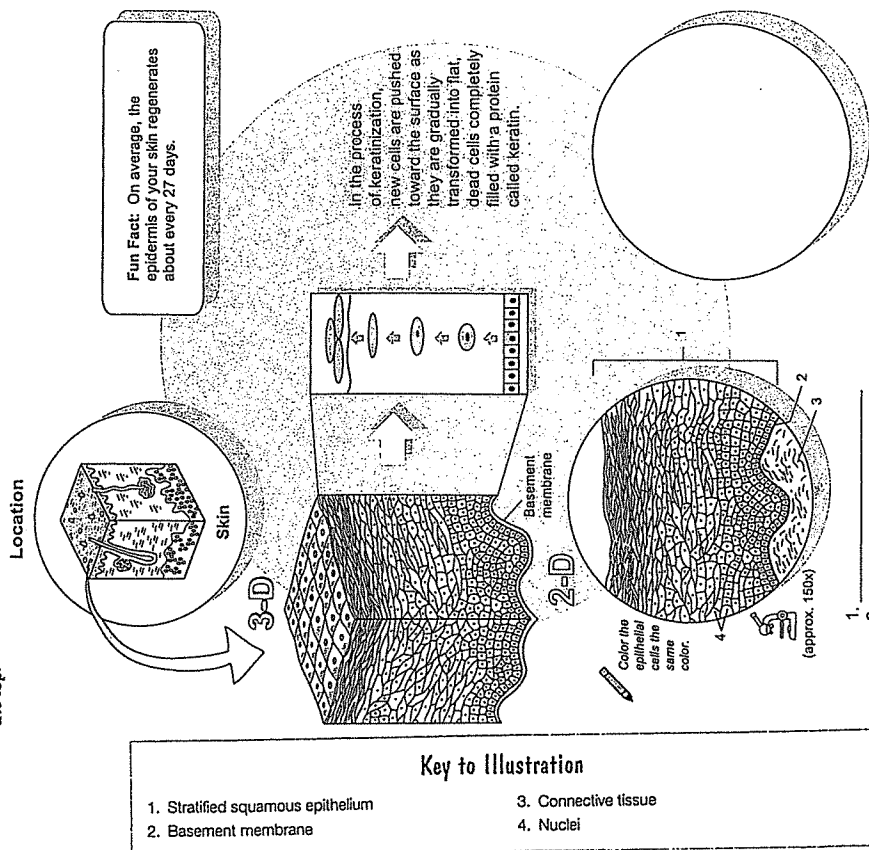
- lining of mouth, pharynx, esophagus, anus, and vagina

**Location**

Provides physical protection against abrasion and pathogens to underlying tissues.

**Tip**

Pattern: Transition in cell shape from cuboidal or columnar cells in the lower region to flat cells on the top.



My drawing of stratified squamous epithelium

**IES—Connective**  
Irregular Connective Tissue

**Location**

Connective tissues primarily give structural support to other tissues and organs in the body. Though they are of a wide variety of types, all are composed of cells, fibers, and ground substance. The most common cell type is called a fibroblast which manufactures the fibers and other extracellular material. The two most common types of protein fibers produced are collagen and elastin. Collagen is for strength and elastin is for elasticity. The cells and the fibers are both embedded in a gel-like material called the ground substance. The ground substance varies in its consistency from being almost like gelatin to a much more rigid material.

There are two types of dense connective tissue in the body, namely, dense *regular* connective and dense *irregular* connective. Dense *irregular* connective tissue is characterized by a random arrangement of collagen fibers and a greater proportion of ground substance.

**Location**

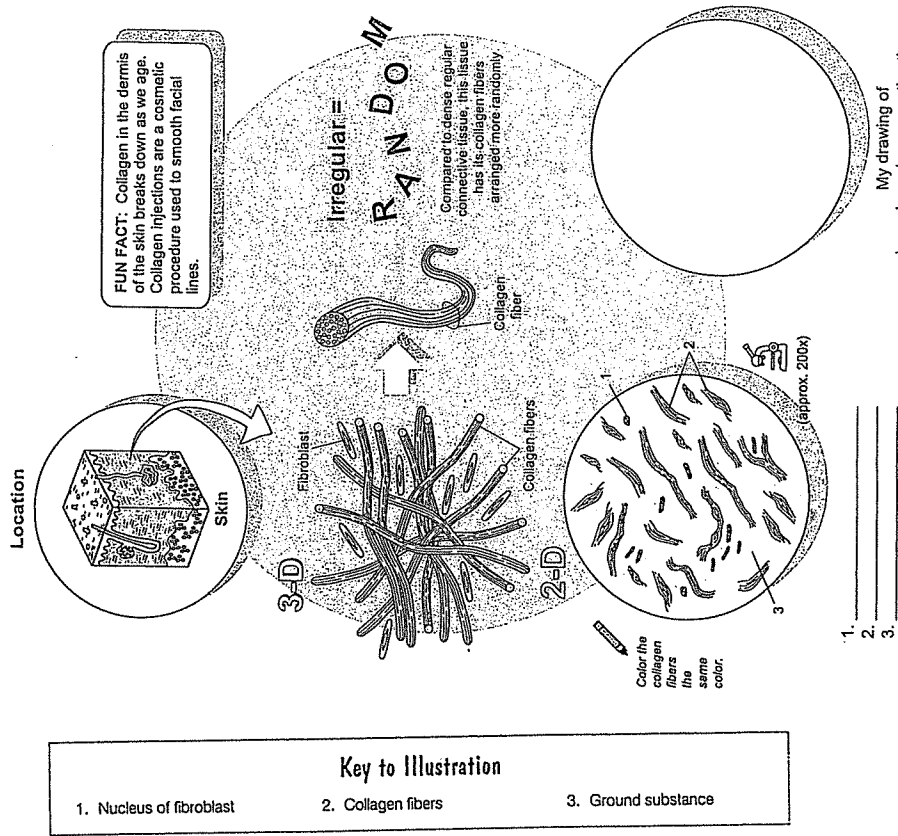
Dermis of the skin; peritoneum; visceral organ capsules; around muscles.

**Location**

Resists stresses applied in many different directions

**Tips**

- o Fibroblasts are more scattered throughout the tissue
- o Collagen fibers are not stacked on top of each other, randomly arranged



My drawing of dense irregular connective tissue