

cription

Connective tissues primarily give structural support to other tissues and organs in the body. Though there are a wide variety of types, all are composed of cells, fibers, and matrix.

Bone is a specialized type of connective tissue that has calcified into a hard substance. It is composed of organic and inorganic substances. The inorganic portion that constitutes about two-thirds of bone mass is made of modified calcium phosphate compounds called hydroxyapatite, while the organic portion is composed of collagen fibers. The two general types of bone are: spongy and compact. Spongy bone is less organized and is found in the ends of long bones and other places. Compact bone is more complex and orderly in structure and is found in the shaft of long bones and other locations.

Let's examine compact bone in more detail. The individual units in compact bone are tall, cylindrical towers called osteons (Haversian systems). In the middle of each osteon is a central canal that serves as a passageway for blood vessels. Around this canal are concentric rings of bony tissue called lamellae. Along each of these rings at regular intervals are small spaces called lacunae that contain a mature bone cell or osteocyte. Branching between individual lacunae are smaller passageways called canaliculi, which allow fluid with dissolved nutrients to travel to osteocytes.

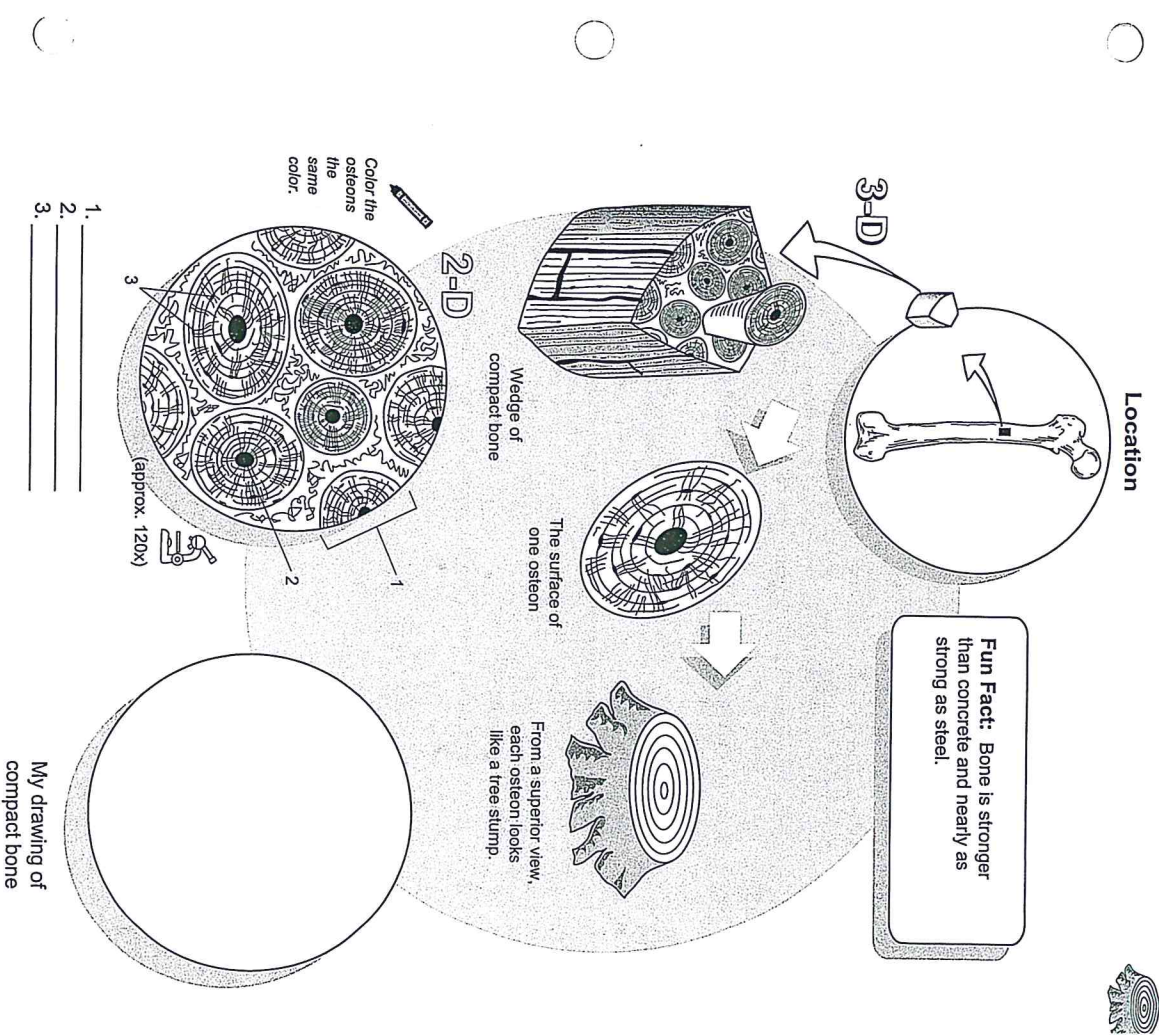
Each surface of an osteon looks like a tree stump. Both structures are made of hard, dense materials. Like the growth rings in a tree, the osteon has concentric rings called lamellae.

ation

Bone supports body and protects vital organs; provides attachments for muscle to form a lever system for movement; stores calcium compounds and fat. Marrow contains stem cells that produce all blood cell types.

Key to Illustration

1. Osteon	2. Central canal	3. Osteocytes inside lacunae
-----------	------------------	------------------------------



cription

Connective tissues primarily give structural support to other tissues and organs in the body. Though there are a wide variety of types, all are composed of cells, fibers, and matrix.

Cartilage is a specialized type of connective tissue. It is characterized by three traits: lacunae, chondrocytes, and a rigid matrix. The matrix is a firm gel material that contains protein fibers and other substances. Within the matrix are small cavities called lacunae. Within the lacunae are living cartilage cells called chondrocytes. Because cartilage lacks blood vessels, chondrocytes rely on the diffusion of nutrients into the matrix to survive.

The three basic types of cartilage in the body are:

- o Hyaline cartilage
- o Elastic cartilage
- o Fibrocartilage

Hyaline cartilage is the most common type of cartilage.

Three dimensionally, a piece of any type of cartilage is similar to a block of Swiss cheese in its structure and general consistency. Though cartilage is much stronger, both are solid and flexible. The cheese itself is the matrix and the holes are the lacunae.

Covers ends of long bones in synovial joints; between ribs and sternum; cartilages of nose, trachea, larynx, and bronchi; most portions of embryonic skeleton.

Structural reinforcement, slightly flexible support; reduces friction within joints.

To identify this tissue either under the microscope or from a photograph, look for the following:

- o This is the only cartilage type with no apparent fibers (they are present but do not stain well).
- o Chondrocytes are evenly scattered within matrix.

ly Tips

ition

tion

logy



Location

Fun Fact: Most of the bones in the fetus are made of hyaline cartilage and later ossify into bone.

3-D

2-D

Color the chondrocytes the same color.

1. _____

2. _____

3. _____

4. _____

A block of cartilage is like a block of Swiss cheese.

My drawing of hyaline cartilage

Key to Illustration

1. Matrix
2. Lacunae
3. Chondrocytes (cartilage cells)
4. Nucleus of a chondrocyte

cription

Connective tissues primarily give structural support to other tissues and organs in the body. Though there are a wide variety of types, all are composed of cells, fibers, and ground substance. The most common cell type is called a fibroblast, which manufactures fibers and other extracellular material. The two most common types of protein fibers produced are collagen and elastin. Collagen is for strength, and elastin is for elasticity. The cells and fibers are both embedded in a gel-like material called the ground substance. The ground substance varies in its consistency from being gelatin-like to a much more rigid material.

Dense regular connective tissue is composed primarily of collagen fibers, so it is also called fibrous connective or collagenous tissue. The body has two types of dense connective tissue: dense regular connective and dense irregular connective. Dense regular connective tissue is characterized by a large proportion of collagen fibers that are stacked on top of each other in an orderly arrangement.

logy

Layers of collagen fibers are strong like the steel cables on a suspension bridge.

ition

Tendons and aponeuroses; ligaments; covering around skeletal muscles.

ction

Anchors skeletal muscle to bone; attaches bone to bone; packages skeletal muscles; stabilizes bones within a joint.

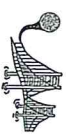ly Tips

- o Fibroblasts are in rows sandwiched between collagen fibers.
- o Collagen fibers are layered in an organized arrangement.

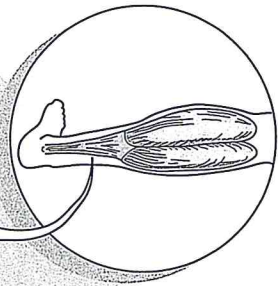
Key to Illustration

1. Collagen fibers

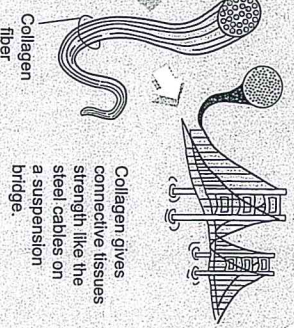
2. Nuclei of fibroblasts



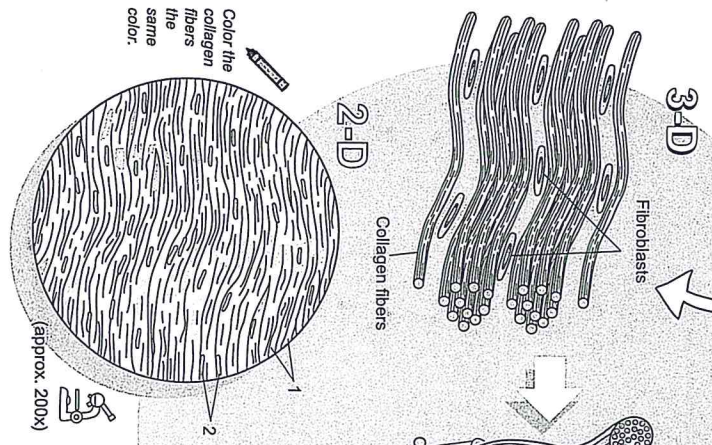
Location



Fun Fact: The calcaneal, or Achilles tendon is the strongest tendon in the body.



Collagen gives connective tissues strength like the steel cables on a suspension bridge.



1. _____
2. _____

My drawing of dense regular connective tissue

Description

Connective tissues primarily give structural support to other tissues and organs in the body. Though there are a wide variety of types, all are composed of cells, fibers, and matrix.

Cartilage is a specialized type of connective tissue. It is characterized by three traits: lacunae, chondrocytes, and a rigid matrix. The matrix is a firm gel material that contains protein fibers and other substances. Within the matrix are small cavities called lacunae. Within the lacunae are living cartilage cells called chondrocytes. Because cartilage lacks blood vessels, chondrocytes rely on the diffusion of nutrients into the matrix to survive.

The three basic types of cartilage in the body are:

- o Hyaline cartilage
- o Elastic cartilage
- o Fibrocartilage

Fibrocartilage is the strongest of the three types because of the presence of many collagen fibers.

Logy

Three dimensionally, a piece of any type of cartilage is similar to a block of Swiss cheese in its structure and general consistency. Though cartilage is much stronger, both are solid and flexible. The cheese itself is the matrix and the holes are the lacunae.

anion

Intervertebral discs; pubic symphysis; pads within knee joint

Shock absorber in a joint; resists compression

dy Tips

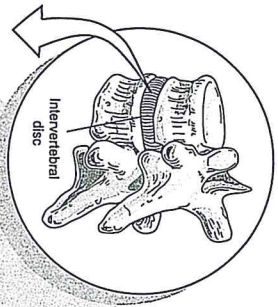
To identify this tissue either under the microscope or from a photograph, look for the following:

- o Has the most collagen fibers of any cartilage.
- o Collagen fibers often appear in a wavy pattern.
- o Chondrocytes are often seen in rows and/or small clusters.

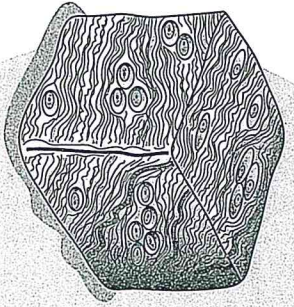
Key to Illustration

1. Lacuna	3. Nucleus of a chondrocyte
2. Chondrocyte	4. Matrix

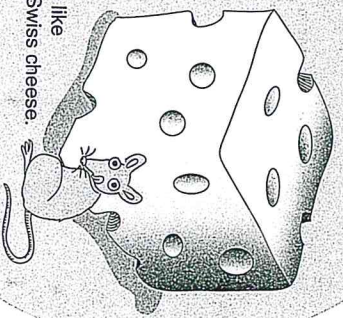
Location



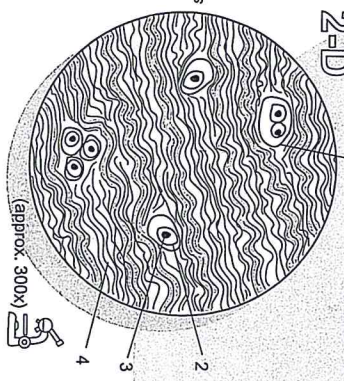
Fun Fact: Cartilage in joints such as the knee undergo the trauma of getting compressed every day.



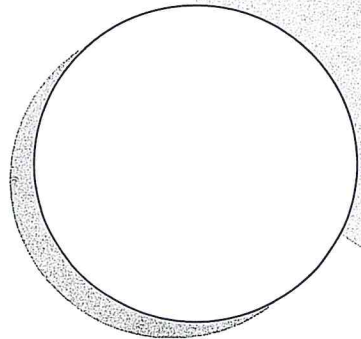
A block of cartilage is like a block of Swiss cheese.



Color the chondrocytes the same color.



1. _____
2. _____
3. _____
4. _____



My drawing of fibrocartilage