

The integument is the covering of the body. In vertebrates (animals with backbones) it is customarily called the skin. It has such a diverse array of structures and functions that it constitutes an entire system in itself. It varies considerably in thickness and structural character according to what is needed. For example, the thickest skin is on the sole of the foot; the thinnest, on the eyelid. Some parts of the skin are quite hairy (hairy); others are virtually hairless. Some areas are more sensitive than others, and so on. The principal function of the skin is protection.

Color titles A through A⁶ and the related structures in the figure as well as in the magnified block of skin. Consider coloring A and A¹ the colors of your own skin and hair. The pigment of skin is restricted to the epidermis only.

The *epidermis* is the epithelial part of the skin. It consists throughout of stratified squamous epithelium with surface layers of flattened, dead cells composed of the protein keratin. These outer layers of dead cells, seen best on the soles of the feet or the palm of the hand, have been separated from their source of nutrition to such an extent that they have dehydrated and dried. But before dying they have synthesized large amounts of keratin so that their remains will leave behind a tough but flexible coating. The surface layer in certain parts of the body has ridges and valleys (not shown) in the form of loops and whorls (technically called *dermatoglyphics*) that make fingerprint identification possible. The deepest layer of the epidermis is made up of germinating cells, which continually divide to replace the outer layers as they are worn off. The cells have no direct blood supply; they obtain their nutrition, water, and other essentials by diffusion from the vessels of the dermis below. The epidermis (especially at deeper levels) contains a pigment, melanin, which darkens the skin; hemoglobin in the blood and carotene (which makes carrots orange) also contribute to skin coloration. Derived from the epidermis are such accessory structures as hair, sweat, sebaceous glands, and *nails*. The most important functions of the epidermis are its resistance to wear-and-tear forces and its prevention of excessive water loss.

Hairs are also made up almost exclusively of the protein keratin. They are formed by epidermal structures called *hair follicles*. These follicles are invaginations (inward growths) of the epidermis that extend deep into the dermis below and encompass the *hair shafts*. The deepest part of

the follicle forms a bulb that contains a mass of dermal tissue (the dermal papilla) with nerves and blood vessels. Each hair follicle has a smooth muscle called the *arrector pili* attached to dermal tissue near the base of the epidermis and the sheath of the lower end of the hair. Fear or cold causes these muscles to contract, raising the hair.

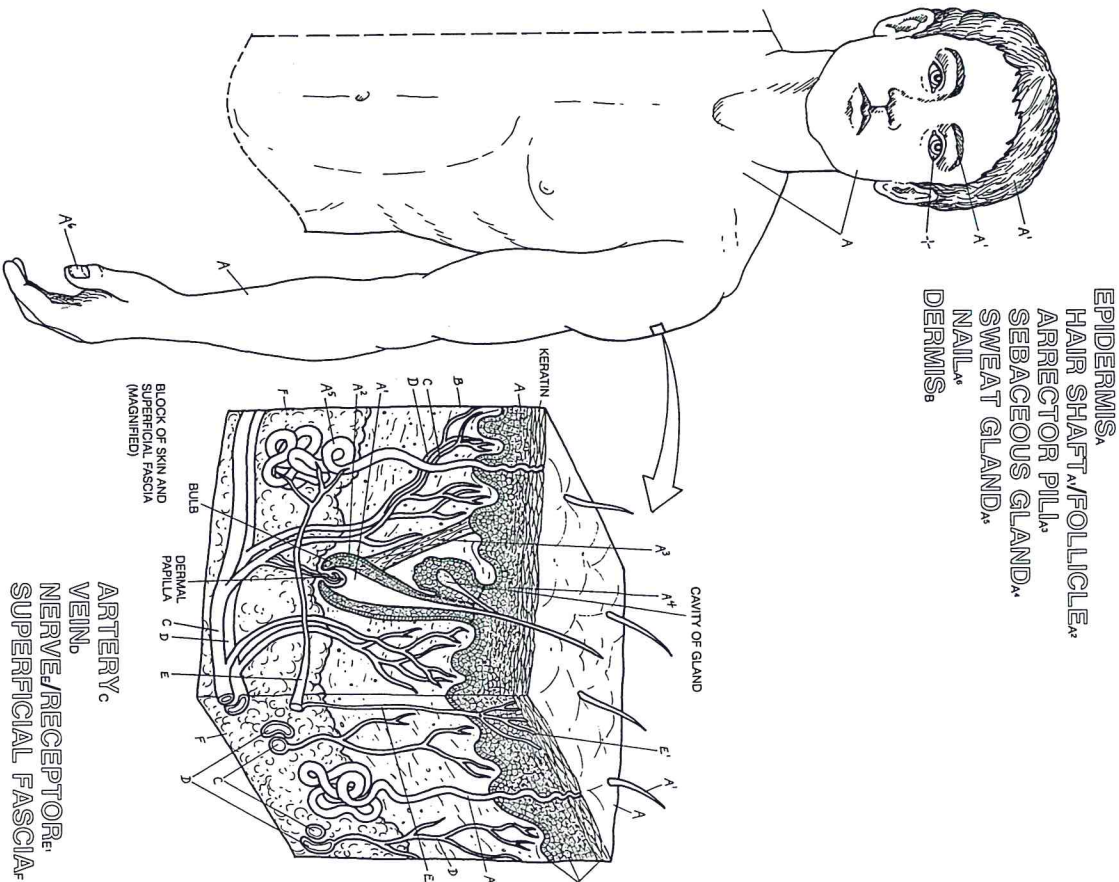
Sebaceous glands, also epithelial derivatives, are glands that have ducts opening into the hair-shaft cavity within the follicle. These exocrine glands secrete a complex lipid substance called sebum, which works its way onto the hair and the surrounding skin and serves as waterproofing. *Sweat glands* consist of coiled tubes derived from the epithelial layer of the epidermis. Their secretion is mostly water with some salt and has the function of cooling the skin by evaporation. Modified sweat glands include the mammary glands of the breast and the ceruminous ("wax-producing") glands of the ear.

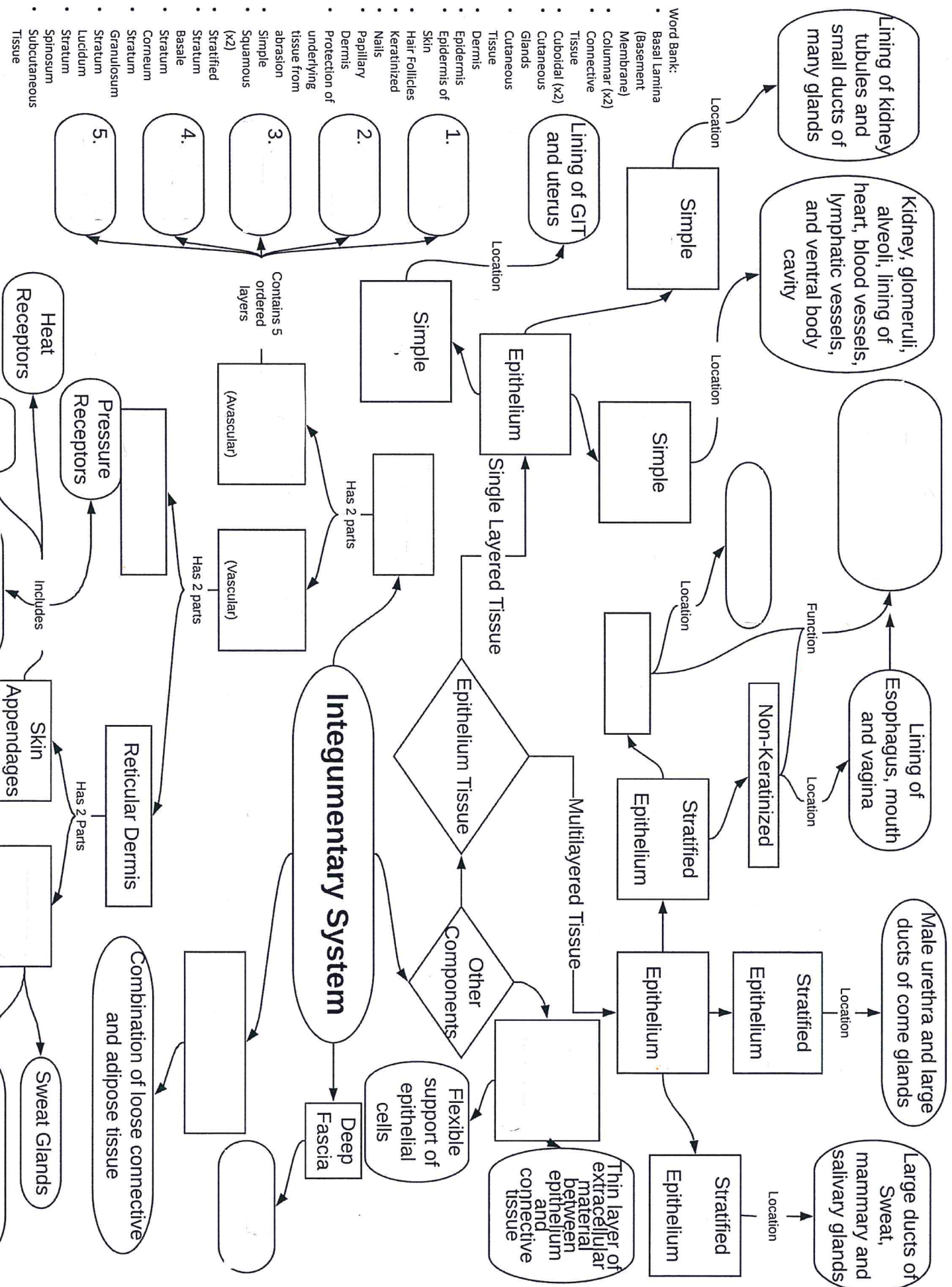
Color titles B through F and the related structures, Color B and F first, preferably with light colors. Color C red, D blue, and E green.

The *dermis* is the connective tissue layer below the epidermis and above the superficial fascia. The fibrous component of the dermis gives security to the epidermis as well as to the dermis itself. The dermis contains a network of blood vessels, nerves, and sensory receptors. *Arteries* are small and supply the dermal papillae and other structures of the dermis. *Veins* conduct deoxygenated blood from the capillary networks of the dermis to larger vessels in the subcutaneous tissues or deeper.

The *nerves* of the skin are both motor (to the arrector pili muscles and the sweat glands) and sensory. The skin is a virtual antenna for reception of sensory information about the environment around us. It contains unencapsulated *receptors* for pain, temperature, and touch (including fibers wrapped around the base of each hair) and encapsulated receptors for pressure and vibration (recall Plate 99).

The *superficial fascia* is a fatty, loose connective tissue layer interposed between the dermis and the underlying deep fascia enveloping skeletal muscle or the perosteum ensheathing bone. The thickness of this layer is subject to variations imposed by diet, stress, and hormones. It conducts arteries, veins, lymphatics, and nerves to the skin. (The diameters of these vessels and nerves are somewhat exaggerated in the drawing.)





Lining of kidney tubules and small ducts of many glands

Kidney, glomeruli, alveoli, lining of heart, blood vessels, lymphatic vessels, and ventral body cavity

Lining of GIT and uterus

Lining of Esophagus, mouth and vagina

Male urethra and large ducts of come glands

Large ducts of Sweat, mammary and salivary glands

Simple

Simple

Stratified Epithelium

Stratified Epithelium

Stratified Epithelium

Stratified Epithelium

Epithelium

Single Layered Tissue

Epithelium Tissue

Multilayered Tissue

Other Components

Flexible support of epithelial cells

Thin layer of extracellular material between epithelium and connective tissue

Integumentary System

Reticular Dermis

Combination of loose connective and adipose tissue

Heat Receptors

Pressure Receptors

Skin Appendages

Sweat Glands

Sebaceous Glands

Contains 5 ordered layers

(Avascular)

(Vascular)

Has 2 parts

Has 2 parts

- 1.
- 2.
- 3.
- 4.
- 5.

- Word Bank:
- Basal lamina (Basement Membrane)
 - Columnar (x2)
 - Connective Tissue
 - Cuboidal (x2)
 - Curvaceous Glands
 - Curvaceous Tissue
 - Derrnis
 - Epidermis of Skin
 - Hair Follicles
 - Keratinized
 - Nails
 - Papillary Derrnis
 - Protection of underlying tissue from abrasion
 - Simple Squamous (x2)
 - Stratified Stratum Basale
 - Stratum Corneum
 - Stratum Granulosum
 - Stratum Lucidum
 - Spinosum
 - Subcutaneous Tissue