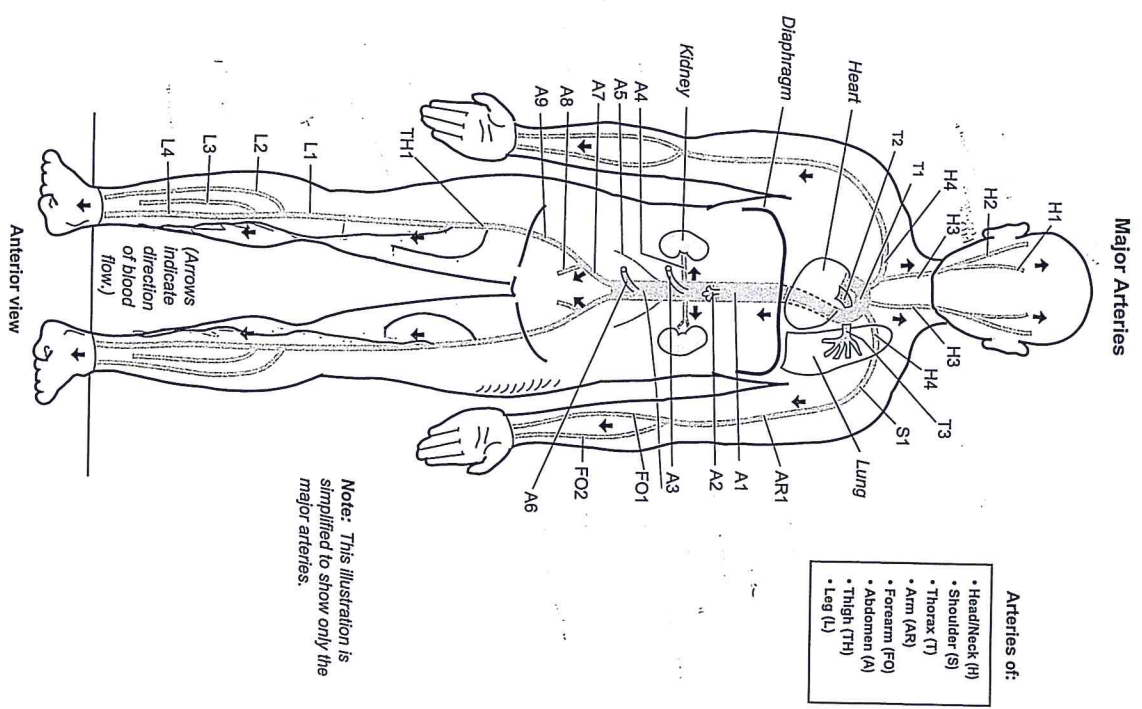


Key to Illustration		
<b>Head/Neck (H)</b>	<b>Forearm (FO)</b>	<b>Thigh (TH)</b>
H1. Internal carotid a.	FO1. Ulnar a.	TH1. Femoral a.
H2. External carotid a.	FO2. Radial a.	<b>Leg (L)</b>
H3. Common carotid a.	<b>Abdomen (A)</b>	L1. Popliteal a.
H4. Subclavian a.	A1. Abdominal aorta	L2. Anterior tibial a.
<b>Shoulder (S)</b>	A2. Celiac trunk	L3. Fibular a.
S1. Axillary a.	A3. Superior mesenteric a.	L4. Posterior tibial a.
<b>Thorax (T)</b>	A4. Renal a.	
T1. Aortic arch	A5. Gonadal a.	
T2. Pulmonary trunk	( <i>testicular a. in males,</i>	
T3. Pulmonary a.	<i>ovarian a. in females</i> )	
<b>Arm (AR)</b>	A6. Inferior mesenteric a.	
AR1. Brachial a.	A7. Common iliac a.	
	A8. Internal iliac a.	
	A9. External iliac a.	



Note: This illustration is simplified to show only the major arteries.

- Arteries of:
- Head/Neck (H)
  - Shoulder (S)
  - Thorax (T)
  - Arm (AR)
  - Forearm (FO)
  - Abdomen (A)
  - Thigh (TH)
  - Leg (L)